

A 29-year-old Female with Nonpuerperal Vaginal Bleeding

Sonal Saran^{1*}, Ravikant Kaushik²

¹Department of Radiodiagnosis, All India Institute of Medical Sciences, Rishikesh, Uttarakhand, India, ²Department of Radiodiagnosis, Doon Government Medical College, Dehradun, Uttarakhand, India

SECTION 1 – Quiz

Case

A 29-year-old female patient presented with painless vaginal bleeding for 12 days. She was G2P2A0 with the youngest child, 6 years old. There was no history of difficult vaginal delivery during any of her pregnancies. A brown and white voluminous vaginal mass was felt with a small amount of vaginal bleeding on per-vaginal examination. Transabdominal ultrasound of the patient was performed, which is shown in Figure 1 and Video 1.

WHAT IS YOUR INTERPRETATION?

Declaration of patient consent

The authors certify that they have obtained all appropriate patient consent forms. In the form, the patient has given her consent for her images and other clinical information to be reported in the journal. The patient understands that her name and initials will not be published and due efforts will be made to conceal identity, but anonymity cannot be guaranteed.

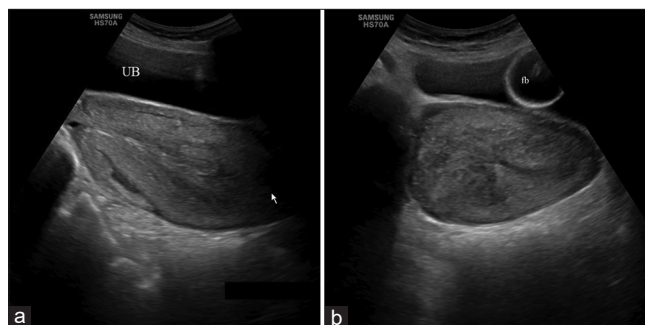


Figure 1: Transabdominal ultrasound image in longitudinal (a) and transverse (b) planes with full urinary bladder (UB) and Foley's bulb (Fb) *in situ*. The arrow points to abnormality

Financial support and sponsorship

Nil.

Conflicts of interest

There are no conflicts of interest.

Received: 20-01-2021 Revised: 05-04-2021 Accepted: 21-05-2021 Available Online: 21-08-2021

Video Available on: www.jmuonline.org

Access this article online

Quick Response Code:



Website:
www.jmuonline.org

DOI:
10.4103/JMU.JMU_15_21

Address for correspondence:

Dr. Sonal Saran,
Department of Radiodiagnosis, All India Institute of Medical Sciences,
Rishikesh, Uttarakhand, India.
E-mail: sonalsaranmalik@gmail.com

This is an open access journal, and articles are distributed under the terms of the Creative Commons Attribution-NonCommercial-ShareAlike 4.0 License, which allows others to remix, tweak, and build upon the work non-commercially, as long as appropriate credit is given and the new creations are licensed under the identical terms.

For reprints contact: WKHLRPMedknow_reprints@wolterskluwer.com

How to cite this article: Saran S, Kaushik R. A 29-year-old female with nonpuerperal vaginal bleeding. J Med Ultrasound 2022;30:314.